

# Lumbar Neuraxial Ultrasound for Spinal and Epidural Anesthesia

## A Systematic Review and Meta-Analysis

Anahi Perlas, MD, FRCPC,\*† Luis E. Chaparro, MD,‡ and Ki Jinn Chin, MD, FRCPC\*†

**Background:** This systematic review examines the evidence for preprocedural neuraxial ultrasound as an adjunct to lumbar spinal and epidural anesthesia in adults.

**Methods:** We searched MEDLINE, EMBASE, and Cochrane Central Register of Controlled Trials databases from inception to June 30, 2014, for randomized controlled trials (RCTs) and cohort studies that reported data answering one or more of the following 3 questions: (1) Does ultrasound accurately identify a given lumbar intervertebral space? (2) Does ultrasound accurately predict the needle insertion depth required to reach the epidural or intrathecal space? (3) Does ultrasound improve the efficacy and safety of spinal or lumbar epidural anesthesia?

**Results:** Thirty-one clinical trials and 1 meta-analysis were included in this review. Data from 8 studies indicate that neuraxial ultrasound can identify a given lumbar intervertebral space more accurately than by landmark palpation alone. Thirteen studies reported an excellent correlation between ultrasound-measured depth and needle insertion depth to the epidural or intrathecal space. The mean difference between the 2 measurements was within 3 mm in most studies. Thirteen RCTs, 5 cohort studies, and 1 meta-analysis reported data on efficacy and safety outcomes. Results consistently showed that ultrasound resulted in increased success and ease of performance. Ultrasound seemed to reduce the risk of traumatic procedures but there was otherwise insufficient evidence to conclude if it significantly improves safety.

**Conclusions:** There is significant evidence supporting the role of neuraxial ultrasound in improving the precision and efficacy of neuraxial anesthetic techniques.

**What's New:** We know that neuraxial ultrasound is a useful complement to clinical examination when performing lumbar central neuraxial blocks. It provides anatomical information including the depth of the epidural space, the identity of a given intervertebral level, and the location of the midline and interspinous/interlaminar spaces. This information can be used to successfully guide subsequent needle insertion.

Since 2010, new data from RCTs and 1 meta-analysis suggest that neuraxial ultrasound increases the success and reduces the technical difficulty of lumbar central neuraxial blocks. Findings from the meta-analysis suggest that neuraxial ultrasound reduces the risk of traumatic procedures, and thus may possibly contribute to the safety of lumbar central neuraxial blocks.

(*Reg Anesth Pain Med* 2016;41: 251–260)

From the \*Department of Anesthesia and Pain Management, Toronto Western Hospital, University Health Network; †Department of Anesthesia, University of Toronto, Toronto, Ontario, Canada; and ‡Department of Anesthesiology, Hospital Pablo Tobón Uribe, Medellín, Colombia.  
Accepted for publication October 10, 2014.

Address correspondence to: Anahi Perlas, MD, FRCPC, University of Toronto, McLaughlin Pavilion 2-405, 399 Bathurst St, Toronto, Ontario, Canada M5T 2S8 (e-mail: Anahi.perlas@uhn.on.ca).

The authors declare no conflict of interest.

Drs Anahi Perlas and Ki Jinn Chin received academic time support through a Research Merit Award 2011–2013 and 2013–2015, respectively, from the Department of Anesthesia, University of Toronto.

Copyright © 2014 by American Society of Regional Anesthesia and Pain Medicine

ISSN: 1098-7339

DOI: 10.1097/AAP.0000000000000184

Spinal anesthesia and lumbar epidural anesthesia are commonly performed anesthetic and/or analgesic techniques with a long track record of efficacy and safety. However, neuraxial blocks can occasionally be challenging to perform, particularly if the spinal anatomy is altered or obscured by factors such as obesity, spinal deformities, or previous spine surgery.<sup>1</sup> Technical difficulty can result in procedural failure, suboptimal epidural analgesia, and increased needle trauma. It may also increase the risk of both minor complications such as postdural puncture headache and backache and major complications including epidural hematoma and spinal cord injury.<sup>2–4</sup>

Neuraxial ultrasound is a recent development in the field of regional anesthesia. A “pre-procedural” ultrasound examination of the spine accurately delineates the underlying relevant anatomy, thus aiding in successful insertion of a spinal or epidural needle; this has also been termed “ultrasound-assisted” neuraxial blockade. Although real-time ultrasound-guided spinal and epidural techniques have been described, they are distinctly different from the ultrasound-assisted approach. They remain experimental at this time and will not be discussed in this review.

The objective of this review was to examine the evidence supporting the use of preprocedural neuraxial ultrasound to facilitate spinal or lumbar epidural anesthesia and, based on this, to set forth recommendations for practice. We addressed 3 distinct clinical questions:

- 1) Does neuraxial ultrasound accurately identify a given lumbar intervertebral space?
- 2) Does neuraxial ultrasound accurately predict the needle insertion depth required to reach the epidural or intrathecal space?
- 3) Does neuraxial ultrasound improve the efficacy and safety of spinal or epidural anesthesia?

## METHODS

For this review, we included all randomized controlled trials (RCTs) and cohort studies involving neuraxial ultrasound and spinal or lumbar epidural anesthesia/analgesia in adult patients. We also included studies involving diagnostic lumbar puncture, given that the needle insertion technique is identical to that of spinal anesthesia. We excluded studies of real-time ultrasound-guided neuraxial blocks as well as those related to interventional pain procedures on the spine. Studies that did not report outcomes related to the 3 primary questions were excluded. We performed a literature search of the MEDLINE, EMBASE, and Cochrane Central Register of Controlled Trials databases from the time of inception until June 30, 2014. The following search terms were used: ultrasound, ultrasonography, epidural, peridural, subarachnoid space, epidural analgesia, epidural anesthesia, spinal anesthesia, and conduction anesthesia. No language restrictions were applied. The abstracts of all references identified by the search were independently reviewed by 2 authors. Full text copies of potentially relevant studies were obtained and again underwent independent review

by 2 authors. Data from studies that met the inclusion criteria were entered into a standardized data extraction form. All disagreements were resolved by discussion and mutual consensus among the 3 authors of this review. We performed a risk of bias assessment for each study. The QUADAS-2 tool<sup>5</sup> was used for studies of diagnostic accuracy of neuraxial ultrasound in identifying lumbar intervertebral spaces. We used the Jadad score<sup>6</sup> and the Cochrane Collaboration's risk of bias assessment tool for RCTs<sup>7</sup> looking at the effect of neuraxial ultrasound on clinical outcomes.<sup>7</sup> We performed meta-analysis using RevMan 5.3 (The Nordic Cochrane Centre, The Cochrane Collaboration, Copenhagen, 2014). The treatment effect was expressed as risk ratio for dichotomous outcomes and as mean difference (MD) for continuous data outcomes, respectively, along with 95% confidence intervals (CIs). Statistical heterogeneity was assessed using both the  $\chi^2$  test and  $I^2$ . The studies that reported on the correlation of the ultrasound-determined depth of the epidural or intrathecal space versus needle insertion depth underwent meta-analysis using R software (version 2.15.3). Fisher z-transformation was applied to the Pearson product moment correlation coefficients before meta-analysis. The final results of pooled z scores were back-transformed to the pooled correlation coefficients.

Summary recommendations follow the format suggested by the US Department of Health and Human Services Agency for Health Care Policy and Research.<sup>8</sup> We followed the reporting recommendations of the PRISMA statement.<sup>9</sup>

## RESULTS

Seven hundred six citations were identified in the initial search of which 57 were selected as potentially relevant and underwent full-text review (Fig. 1). Of these, we excluded 25 studies for the following reasons: 9 were narrative reviews or descriptive articles, 6 were in the pediatric population, 6 involved interventions on the thoracic or cervical spine, and 4 were case reports. One meta-analysis was identified and included in this review.<sup>10</sup>

### Does Neuraxial Ultrasound Accurately Identify a Given Lumbar Interspace?

Eight studies<sup>11-18</sup> involving a total of 624 patients addressed this question (Table 1). All 8 studies used a “counting-up” approach in which the ultrasound probe was placed in a longitudinal orientation over the sacrum (identified as a continuous hyperechoic line) and then moved cephalad to identify successive spinous processes or laminae and the corresponding interspinous or interlaminar spaces.<sup>19</sup> A low-frequency curved-array probe was used in all studies except one.<sup>16</sup> These 7 studies were generally of good quality according to the QUADAS-risk of bias assessment tool for diagnostic studies, with only 2 studies receiving a “high” rating in one domain each. Five studies examined the agreement between ultrasound and palpation of surface landmarks in identifying a given intervertebral space.<sup>13-15,17,18</sup> None of these studies, however, verified accuracy against a more

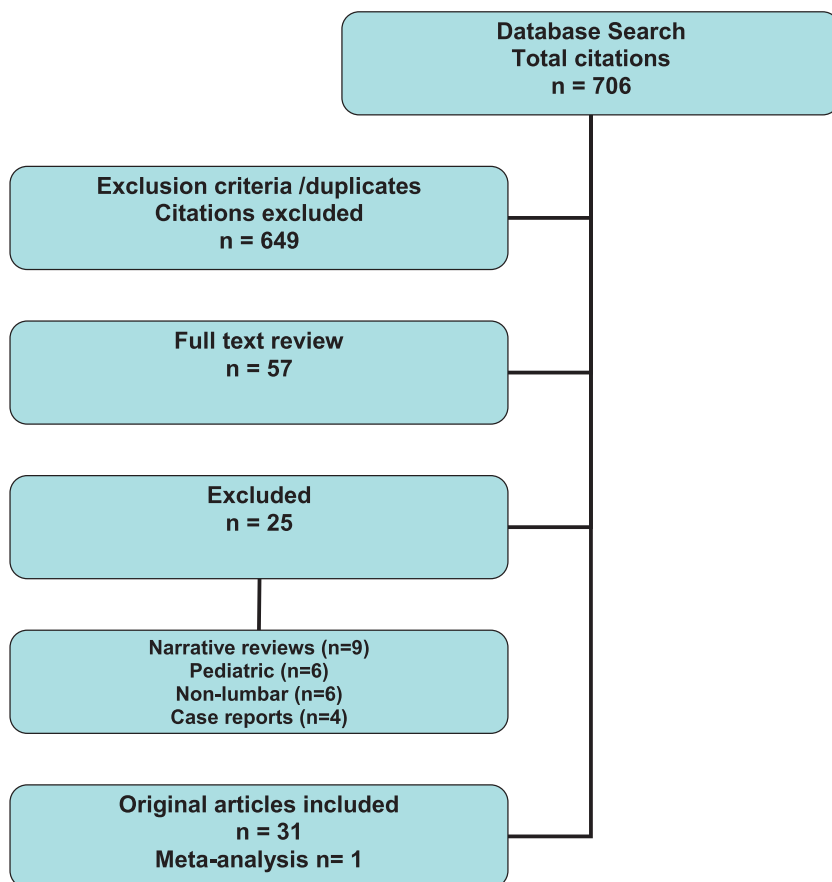


FIGURE 1. Flow chart of database search and study selection.

**TABLE 1.** Studies Reporting Accuracy of Intervertebral Space Identification

Author	Year	Country of Origin	n	Separate Reference Standard	Primary Outcome	Main Findings
Furness	2002	United Kingdom	50	X-ray	Accuracy L3-4	Ultrasound 71% accurate Palpation 30% accurate
Duniec	2013	Poland	122	Palpation	Agreement	64% agreement 18% higher by palpation by 1 level 0.8% higher by palpation by 2 levels 16.4% lower by palpation by 1 level 0.8% lower by palpation by 2 levels
Halpern	2010	Canada	74	CT scan	CUSUM analysis for 90% accuracy	90% accuracy after 22 and 36 scans
Lee	2011	United States	51	Palpation	Agreement	14% agreement 23% higher by palpation by 1 level 25% higher by palpation by >1 level
Locks	2010	Brazil	90	Palpation	Agreement at L3-4	50% agreement
Schlotterbeck	2008	United Kingdom	99	Palpation	Agreement	36% agreement 50% higher by palpation 14% lower by palpation
Watson	2001	United Kingdom	17	MRI	US accuracy at L3-4	76.5% accuracy (13/17) 23.5% off by 1 level
Whitty	2008	Canada	121	Palpation	Agreement	55% agreement 32% higher by palpation

established gold-standard imaging modality (the reference standard). Schlotterbeck et al<sup>15</sup> and Whitty et al<sup>17</sup> both studied a retrospective cohort of patients who had received labor epidural analgesia and in whom the documented level of epidural insertion was correlated with ultrasonographic identification of the intervertebral level corresponding to the visible skin puncture site. They excluded patients with multiple puncture marks or who had inadequate documentation of epidural insertion site. For these reasons, they received a “high” risk of bias rating in the “flow and timing” domain of the QUADAS-2 tool. In all 5 studies, the agreement between ultrasound and palpation-determined interspaces was generally poor with rates ranging from 14% to 64%. In cases of disagreement, palpation-determined landmarks were usually higher than ultrasound-determined landmarks (52%–78% of cases) and often erred by more than one interspace.

The remaining 3 studies used x-ray, magnetic resonance imaging (MRI), or computed tomographic (CT) scan as a separate reference standard to verify intervertebral level.<sup>11,12,16</sup> Using plain x-ray of the lumbar spine as a reference standard, Furness et al<sup>11</sup> demonstrated that ultrasound correctly identified individual interspaces (from L2-3 to L4-5) 71% of the time, whereas palpation was only correct 29% of the time. Furthermore, the margin of error never exceeded one level with ultrasound, but was up to 2 spaces higher or lower in 27% of palpation assessments. These findings are consistent with those reported by Watson et al<sup>16</sup> who, using MRI as their reference standard, found that ultrasound accurately identified the L3-4 interspace in 76% of cases with a margin of error that did not exceed one level.

Finally, in a learning curve study that used CT as a reference standard, Halpern et al<sup>12</sup> reported an overall identification accuracy rate for ultrasound of 68%. However, analysis of the learning curve showed that the 2 anesthesiologists in the study with no previous experience with neuraxial ultrasound achieved accuracy rates of 90% or greater after 22 and 36 procedures, respectively.

### Recommendation

There are consistent data (evidence level IIa) to suggest that neuraxial ultrasound identifies lumbar intervertebral levels, with greater accuracy than palpation of surface anatomical landmarks (grade B recommendation).

### Does Neuraxial Ultrasound Accurately Predict the Needle Insertion Depth Required to Reach the Epidural or Intrathecal Space?

Thirteen studies involving a total of 875 patients examined the correlation between ultrasound-measured depth and actual needle insertion depth required to reach the epidural or intrathecal space (Table 2).<sup>20–32</sup> Nine studies were performed in obstetric patients,<sup>20,21,23,24,27–29,31,32</sup> 3 in non-obstetric surgical patients (urology, vascular, and orthopedics),<sup>22,26,30</sup> and 1 in patients requiring a diagnostic lumbar puncture in the emergency department.<sup>25</sup> The quality of the studies was generally good, with the most common deficiency being unclear patient selection criteria. Two studies<sup>30,32</sup> received a “high” risk of bias rating in the reference standard domain because of lack

**TABLE 2.** Studies Reporting Accuracy of Ultrasound Measurement of Epidural Space Depth

Author	Year	Country of Origin	Sample Size (n)	Pearson CC (r)	Bland-Altman Analysis			Patients	Structure Evaluated
					Mean, mm	SD, mm	LOA (95% CI), mm		
Arzola	2007	Canada	61	0.88	0.1	3.5	-6.6 to 6.9	Obstetrics	LF-D complex
Balki	2009	Canada	48	0.84	3.0		-7.0 to 13.0	Obstetrics	LF-D complex
Chin	2009	Canada	50	0.82	2.1		-8.5 to 12.7	Orthopedics	LF-D complex and PVB
Cork	1980	United States	36	0.98				Obstetrics	Lamina
Currie	1984	United Kingdom	75	0.96				Obstetrics	Lamina
Ferre	2009	United States	39	0.80				ER patients for LPs	LF-D complex
Gnaho	2012	France	31	0.98	2.2	1.8	-1.4 to 5.8	Orthopedics	LF-D complex
Grau AAS	2001	Germany	36	0.93	7.9			Obstetrics	LF-D complex
Grau RAPM	2001	Germany	80	0.96	2.0	2.3	-3 to 7	Obstetrics	LF-D complex
Grau	2002	Germany	150	0.91	1.7		-6.0 to 8.0	Obstetrics	LF-D complex
Helayel	2010	Brazil	60	0.66	0.04	0.1	-2.3 to 2.2	Orthopedics, urology, vascular	LF-D complex
Tran	2009	Canada	20	0.89	-4.8		-14.8 to 5.2	Obstetrics	LF-D complex
Vallejo	2010	United States	189	0.91				Obstetrics	LF-D complex

of blinding (ie, the anesthesiologist performing the epidural procedure was aware of the ultrasound-measured depth to the epidural space) (Table 3). The Pearson correlation coefficient reported by the individual studies ranged from 0.66 to 0.98.<sup>23,26,30</sup> The pooled Pearson product moment correlation coefficient was 0.91 (95% CI, 0.87–0.94), using a random-effects model to account for heterogeneity, suggesting the ultrasound-measured depth of the epidural space was highly correlated with the depth of the epidural space measured during the epidural needle insertion (Fig. 2). Four studies measured depth to the epidural space using a longitudinal parasagittal oblique ultrasound view<sup>23–25,31</sup>; 3 of these studies also used a linear-array probe.<sup>23–25</sup> All other studies used a low-frequency curved-array probe and measured depth to the epidural/intrathecal space in the transverse midline ultrasound view. A midline

approach was used for needle insertion in all studies. The ultrasound landmark used for measuring depth to the epidural space in most studies was the ventral aspect of the hyperechoic ligamentum flavum-dura mater complex (Table 2). The older studies by Cork et al and Currie measured depth to the ventral surface of the laminae; this choice, however, reflects the technological limitations of ultrasound visualization at the time. Despite these minor variations in method, there was excellent correlation between ultrasound-measured depth and actual needle insertion depth in all studies. It should be noted, however, that a strong linear correlation does not necessarily imply accuracy. To evaluate the accuracy of the ultrasound measurement, 8 of the more recent studies also performed a Bland-Altman analysis to study the extent to which the 2 depth measurements differed.<sup>20–23,28–31</sup> The ultrasound-determined depth of the

**TABLE 3.** Risk of Bias Assessment of Studies Reporting the Accuracy of Epidural Space Depth

Author	Year	Country of Origin	Risk of Bias				Applicability Concerns		
			Patient Selection	Index Test	Reference Standard	Flow and Timing	Patient Selection	Index Test	Reference Standard
Arzola	2007	Canada	Low	Low	Low	Low	Low	Low	Low
Balki	2009	Canada	Low	Low	Low	Low	Low	Low	Low
Chin	2009	Canada	Low	Low	High	Low	Low	Low	Low
Cork	1980	United States	Unclear	Low	Low	Low	Low	Low	Low
Currie	1984	United Kingdom	Unclear	Low	Low	Low	Low	Unclear	Low
Ferre	2009	United States	Low	Low	Low	Low	Low	Low	Low
Gnaho	2012	France	Unclear	Low	Low	Low	Low	Low	Low
Grau AAS	2001	Germany	Low	Low	Unclear	Low	Low	Low	Low
Grau RAPM	2001	Germany	Unclear	Low	Low	Low	Low	Low	Low
Grau	2002	Germany	Unclear	Low	Low	Low	Low	Low	Low
Helayel	2010	Brazil	Unclear	Low	High	Low	Low	Low	Low
Tran	2009	Canada	Unclear	Low	Low	Low	Low	Low	Low
Vallejo	2010	United States	Low	Low	High	Low	Low	Low	Low

Risk of bias assessment as per the Cochrane Collaboration's tool.<sup>7</sup>



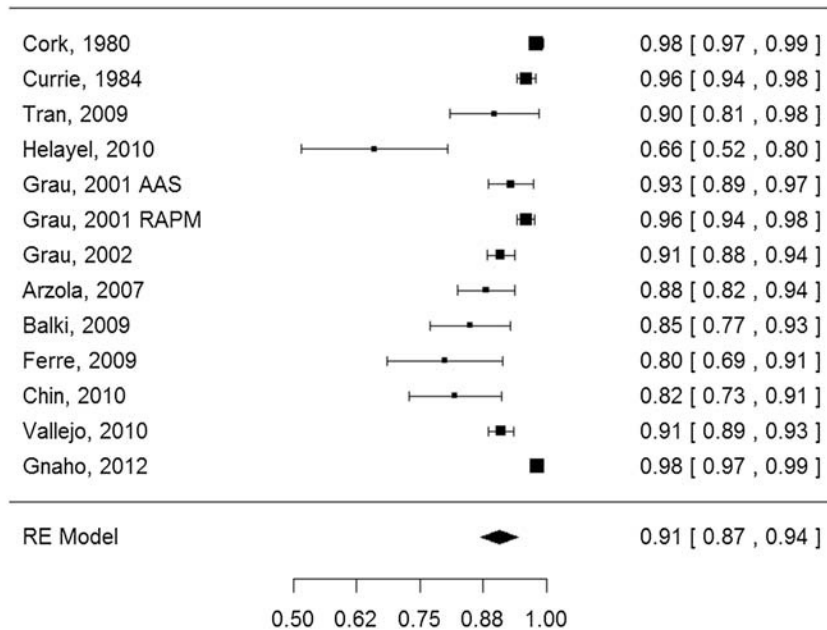


FIGURE 2. Meta-analysis of studies reporting the correlation of ultrasound-measured versus needle depth of the epidural or intrathecal space.

epidural or intrathecal space was found to be accurate within 1 to 13 mm of actual needle insertion depth, with 7 of the 8 studies reporting an MD of less than or equal to 3 mm. The tendency in most studies was for ultrasound to underestimate needle insertion depth; this has been attributed to tissue compression by the probe during the scan.

**Recommendation**

Data from 13 prospective comparative studies (evidence level Ia) consistently show that preprocedure neuraxial ultrasound can be used to accurately predict the needle insertion depth required to reach the epidural or intrathecal space (grade A recommendation).

**Does Neuraxial Ultrasound Improve the Efficacy or Safety of Neuraxial Techniques?**

Fourteen RCTs involving 1768 patients<sup>27–29,32–42</sup> (Table 4) and 5 prospective cohort studies involving 227 patients<sup>20–22,25,26</sup> examined efficacy and safety outcomes. Eight RCTs<sup>27–29,32,34,36,38,42</sup> and 2 cohort studies<sup>20,21</sup> evaluated epidural analgesia in obstetric patients, whereas 3 RCTs<sup>33,37,39</sup> and 2 cohort studies<sup>22,26</sup> evaluated spinal anesthesia in orthopedic procedures. The remaining 3 RCTs<sup>35,40,41</sup> and 1 cohort study<sup>25</sup> each evaluated diagnostic lumbar punctures by emergency physicians. Three RCTs<sup>27,33,36</sup> and 1 cohort study<sup>21</sup> enrolled only patients in whom technical difficulty was expected due to obesity,<sup>21,27,33,36</sup> documented lumbar scoliosis,<sup>33</sup> or previous lumbar spine surgery.<sup>33</sup> The risk of bias assessment showed the RCTs to be of reasonable quality, with the commonest deficiency being lack of blinding of the patient and study personnel (Figs. 3 and 4), a limitation that is often difficult to overcome in procedural studies of this nature.

Thirteen RCTs that reported the risk of technical failure were meta-analyzed (Fig. 5). The combined risk ratio of technical failure was 0.51 (95% CI, 0.32–0.80) when ultrasound guidance was used compared to palpation. In addition, meta-analysis from 8 RCTs suggests that ultrasound guidance results in a lower number of needle passes required for success (Fig. 6).

Safety outcomes were consistently reported as secondary outcome measures; thus, none of the individual studies were designed or sufficiently powered to study these outcomes. Four studies reported a nonsignificant trend toward a lower incidence of headache and backache favoring ultrasound.<sup>27,29,34,42</sup> There was no difference in the reported rate of unintended dural punctures, which was universally low (<1%).<sup>29,32</sup> Only 1 study reported a lower incidence of “puncture site hemorrhage” of 7% with ultrasound versus 20% in the control group.<sup>36</sup> No major complications such as epidural hematoma, epidural abscess, or intracord injections were reported in any of the RCTs.

A recent meta-analysis also addressed the question of whether neuraxial ultrasound can reduce the technical failure of lumbar puncture or epidural catheterization.<sup>10</sup> The studies included were heterogeneous (both preprocedure as well as real-time ultrasound guidance, and both adult and pediatric patients were included). Nevertheless, the findings were consistent with those of our meta-analysis reported in the present review. Pooled data from 12 RCTs showed a 79% reduction in the risk of failed lumbar puncture or epidural catheterization (relative risk, 0.21; 95% CI, 0.1–0.43, *P* < 0.001) with neuraxial ultrasound. They also found a significant reduction in the number of needle re-directions required for success (MD, –1.00; 95% CI, –1.24 to –0.75, *P* < 0.001). Pooled data from 5 RCTs showed a 73% reduction in the risk of a traumatic procedure (relative risk, 0.27; 95% CI, 0.11–0.67, *P* = 0.05), which was defined as visible blood on aspiration or a fluid red blood cell count above a predetermined threshold. The authors further calculated the number needed to treat to prevent one procedural failure and one traumatic procedure as 16 and 17, respectively.

**Recommendation**

Data from 14 RCTs and 2 meta-analysis (this article and 1 previously published) (level of evidence Ia) support the conclusion that neuraxial ultrasound increases the efficacy of lumbar epidural or spinal anesthesia by decreasing the risk of technical failure and the number of needle punctures required, both in patients with normal surface landmarks and those at

**TABLE 4.** RCTs Reporting Efficacy and/or Safety Outcomes of Ultrasound-Assisted Neuraxial Techniques

Author	Year	Country	Technique	Study Design	Sample Size	Patient Population	Primary Outcome	Secondary Outcomes	Jadad Score
Abdelhamid	2013	Egypt	Spinal	RCT	90	Adult unspecified	First attempt success	Procedure time, patient satisfaction	2
Ansari	2014	UAE	Spinal	RCT	150	OB	Procedure time	No. needle insertions/passes, headache, backache, patient satisfaction	3
Chin	2011	Canada	Spinal	RCT	120	Orthopedic difficult spine	First attempt success	No. needle insertions/passes, failure rate, procedure time	5
Grau AAS	2001	Germany	Epidural	RCT	72	OB	No. punctures, no. levels	Failure rate, headache, backache	2
Grau RAPM	2001	Germany	CSE	RCT	80	OB difficult spine	No. punctures, procedure time		1
Grau	2002	Germany	Epidural	RCT	300	OB	Agreement US-CP	Unintended dural punctures, complete analgesia	2
Grau	2004	Germany	CSE	RCT	30	OB	No. punctures	Procedure time, duration of blockade	2
Lim	2014	Singapore	Spinal	RCT	170	Non-OB	First attempt success	No. needle redirections, procedure time, paresthesia, traumatic taps, patient satisfaction	3
Mofidi	2013	Iran	LP	RCT	80	ER	Procedure time	No. needle insertions, traumatic taps, pain score	2
Nomura	2007	United States	LP	RCT	46	ER	Success of LP	No. attempts	4
Peterson	2014	United States	LP	RCT	100	ER	Success of LP	No. needle insertions, traumatic taps, procedure time, pain score, patient satisfaction	2
Sahin	2014	Turkey	Spinal	RCT	100	OB	First attempt success	No. needle insertions/passes/levels attempted, failure rate, procedure time, paresthesia, headache, backache	4
Vallejo	2010	United States	Epidural	RCT	370	OB	Incidence of epidural catheter replacement	No. attempts, unintended dural puncture	3
Wang	2012	China	CSE	RCT	60	OB obese patients	First attempt success	Procedure time, complications, puncture site hemorrhage	2

risk of difficult insertion due to obesity, scoliosis, or previous spine surgery (grade A recommendation).

## DISCUSSION

Although the feasibility of neuraxial ultrasound imaging was first reported several decades ago,<sup>23,24</sup> it was not until the early 2000s that the role of neuraxial ultrasound as we understand it today became established following pioneering work by Grau et al and significant advances in ultrasound technology resulting in greater resolution.<sup>27–29,34</sup> Since a previous review,<sup>43</sup> more data have become available for non-obstetric patients<sup>22,25,26,33,37,39–41</sup> and for patients presumed at risk for difficult insertion due to obesity, scoliosis, or previous surgery.<sup>33</sup> These special patient populations are clinically important because they are at increased risk for technical difficulty. The present review identified 31 studies that addressed at least 1 of 3 driving clinically relevant questions.

Studies evaluating the “diagnostic” performance of ultrasound as an extension of the physical examination consistently show that it enhances the accuracy of landmark identification compared with palpation of surface landmarks alone, and that it accurately measures the depth of the epidural space. A growing body of evidence suggests that the additional anatomical

information provided by neuraxial ultrasound results in increased efficacy as evidenced by a reduction in the risk of failure and a lower number of needle passes required for success.

Epidural hematoma and spinal cord injury due to unintended intracord injection are rare but serious complications of neuraxial anesthesia.<sup>4</sup> Multiple insertion attempts and “traumatic insertion” increase the risk of epidural hematoma<sup>4,44</sup> and an inaccurate assessment of the location of intervertebral spaces can lead to unintended intracord injection resulting in spinal cord injury and permanent neurologic sequelae.<sup>45,46</sup> Given the very low baseline incidence of these catastrophic complications (usually less than 1 in 100,000 cases), it is not feasible to design prospective studies to conclusively prove that image guidance improves safety. However, the evidence strongly suggests that preprocedure neuraxial ultrasound prevents the occurrence of several well-recognized mechanisms of injury.

By increasing the accuracy of needle placement and decreasing the number of needle passes, ultrasound may result in less traumatic procedures, likely contributing to the prevention of epidural hematoma.<sup>23–25,29,32</sup> Similarly, by improving the accuracy of intervertebral space identification, a preprocedure spinal ultrasound could help prevent injuries to the conus medullaris that are consistently associated with a higher-than-intended needle insertion point resulting from imprecise surface

	Random sequence generation (selection bias)	Allocation concealment (selection bias)	Blinding of participants and personnel (performance bias)	Blinding of outcome assessment (detection bias)	Incomplete outcome data (attrition bias)	Selective reporting (reporting bias)
Abdelhamid 2013	?	+	-	-	+	+
Ansari 2014	+	?	-	+	+	+
Chin 2011	+	+	+	-	+	+
Grau 2002	?	+	-	-	+	?
Grau 2004	?	+	-	-	+	+
Grau AAS 2001	?	+	?	-	+	+
Grau RAPM 2001	?	?	-	-	+	+
Lim YC 2014	+	+	-	-	+	+
Mofidi 2013	?	?	-	-	+	+
Nomura 2007	+	+	+	?	+	+
Peterson 2014	?	+	-	-	+	+
Sahin 2014	?	+	+	?	+	+
Vallejo 2010	+	?	-	?	+	+
Wang 2012	?	?	?	?	+	+

FIGURE 3. Risk of bias of individual RCTs reporting efficacy and safety outcomes following the Cochrane Risk of Bias assessment tool for RCTs.

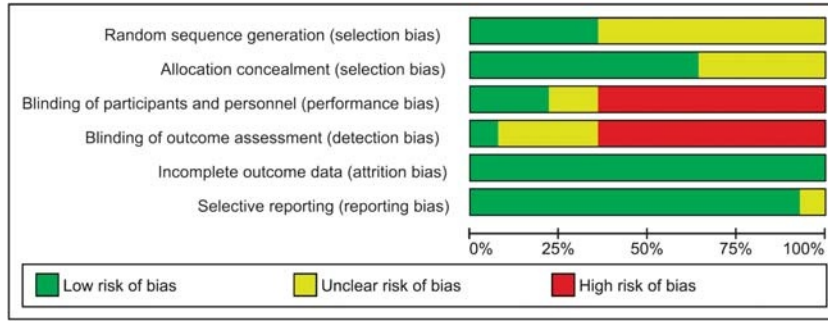


FIGURE 4. Summative risk of bias of RCTs reporting efficacy and safety outcomes following the Cochrane Risk of Bias assessment tool for RCTs.

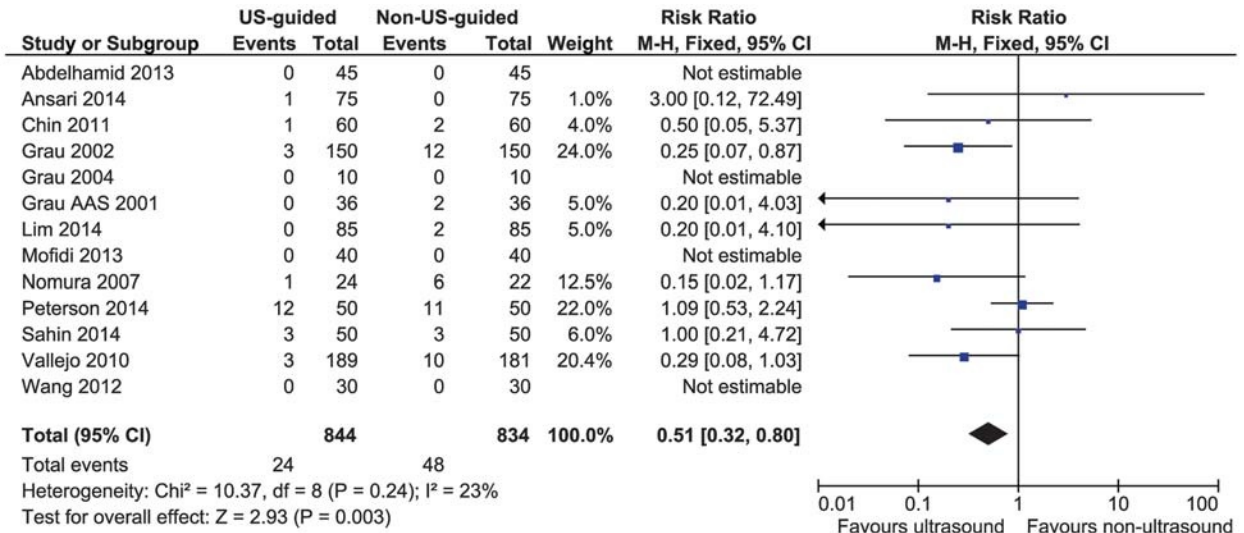


FIGURE 5. Meta-analysis of RCTs (using RevMan 5.3, the Cochrane Collaboration) reporting the risk of technical failure of neuraxial procedures with and without ultrasound imaging.

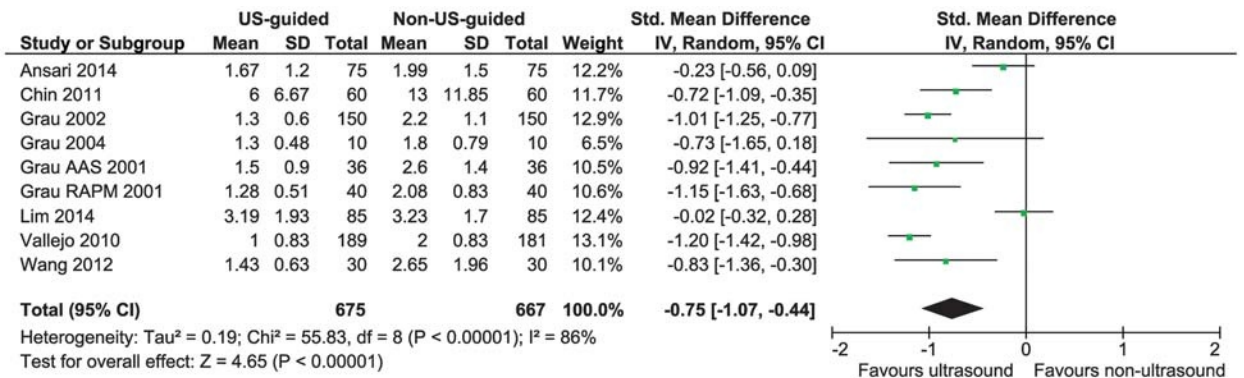


FIGURE 6. Meta-analysis of RCTs (using RevMan 5.3, the Cochrane Collaboration) reporting the number of needle passes required for neuraxial procedure success with and without ultrasound imaging.



**TABLE 5.** Summary Statements, Grades of Recommendations, and Supporting Level of Evidence

Outcome	Grade of Recommendation	Level of Evidence
Increased accuracy of identification of lumbar interspaces	B	Ila
Accurate measurement of the depth of the epidural and intrathecal space	A	Ia
Improved efficacy of neuraxial anesthesia	A	Ia
Improved safety of neuraxial anesthesia	B	III

Following the format suggested by the US Department of Health and Human Services Agency for Health Care Policy and Research.<sup>8</sup>

landmarks.<sup>11,12,16,17</sup> Therefore, level III evidence supports a grade B recommendation that neuraxial ultrasound may help improve the safety of neuraxial anesthesia (Table 5).

#### ACKNOWLEDGMENT

The authors thank Ying Qi from Mississauga, Ontario, for her support with statistical analysis and meta-analysis of correlation studies.

#### REFERENCES

- De Filho GR, Gomes HP, de Fonseca MH, Hoffman JC, Pederneiras SG, Garcia JH. Predictors of successful neuraxial block: a prospective study. *Eur J Anaesthesiol.* 2002;19:447–451.
- Harrison DA, Langham BT. Spinal anaesthesia for urologic surgery. A survey of failure rate, postdural puncture headache and patient satisfaction. *Anaesthesia.* 1992;47:902–903.
- Horlocker TT, McGregor DG, Matsushige DK, Schroeder DR, Besse JA. A retrospective review of 4767 consecutive spinal anesthetics: central nervous system complications. Perioperative Outcomes Group. *Anesth Analg.* 1997;84:578–584.
- Wulf H. Epidural anaesthesia and spinal hematoma. *Can J Anaesth.* 1996; 43:1260–1271.
- Whitting PF, Rutjes AWS, Westwood ME, et al. QUADAS-2: a revised tool for the quality assessment of diagnostic accuracy studies. *Ann Intern Med.* 2013;155:529–536.
- Jadad AR, Moore RA, Carroll D, et al. Assessing the quality of reports of randomized clinical trials: is blinding necessary? *Control Clin Trials.* 1996; 17:1–12.
- Higgins JPT, Altman DG, Gotzsche PC, et al. The Cochrane Collaboration's tool for assessing risk of bias in randomized trials. *BMJ.* 2011;343:d5928.
- US Department of Health and Human Services Agency for Health Care Policy and Research. *Acute Pain Management: Operative or Medical Procedures and Trauma. Clinical Practice Guideline I.* Rockville, MD: AHCPR; 1993. AHCPR Publication 92-0023-0107.
- Moher D, Liberati A, Tetzlaff J, Altman DG, and the PRISMA Group. Preferred reporting items for systematic reviews and meta-analyses: the PRISMA statement. *Ann Intern Med.* 2009;151:264–269.
- Shaikh F, Brzezinski J, Alexander S, et al. Ultrasound imaging for lumbar punctures and epidural catheterisations: systematic review and meta-analysis. *BMJ.* 2013;346:f1720.
- Furness G, Reilly MP, Kuchi S. An evaluation of ultrasound imaging for identification of lumbar intervertebral level. *Anaesthesia.* 2002;57:277–280.
- Halpern SH, Banerjee A, Stocche R, Glanc P. The use of ultrasound for lumbar spinous process identification: a pilot study. *Can J Anaesth.* 2010; 57:817–822.
- Lee AJ, Ranasinghe JS, Chehade JM, et al. Ultrasound assessment of the vertebral level of the intercrystal line in pregnancy. *Anesth Analg.* 2011; 113:559–564.
- Locks Gde F, Almeida MC, Pereira AA. Use of the ultrasound to determine the level of lumbar puncture in pregnant women. *Rev Bras Anesthesiol.* 2010;60:13–19.
- Schlottbeck H, Schaeffer R, Dow WA, Touret Y, Bailey S, Diemunsch P. Ultrasonographic control of the puncture level for lumbar neuraxial block in obstetric anaesthesia. *Br J Anaesth.* 2008;100:230–234.
- Watson MJ, Evans S, Thorp JM. Could ultrasonography be used by an anaesthetist to identify a specified lumbar interspace before spinal anaesthesia? *Br J Anaesth.* 2003;90:509–511.
- Whitty R, Moore M, Macarthur A. Identification of the lumbar interspinous spaces: palpation versus ultrasound. *Anesth Analg.* 2008;106:538–540, table of contents.
- Duniec L, Nowakowski P, Kosson D, Lazowski T. Anatomical landmarks based assessment of intravertebral space level for lumbar puncture is misleading in more than 30%. *Anaesthesiol Intensive Ther.* 2013;45:1–6.
- Chin KJ, Karmakar MK, Peng P. Ultrasonography of the adult thoracic and lumbar spine for central neuraxial blockade. *Anesthesiology.* 2011;114: 1459–1485.
- Arzola C, Davies S, Rofaeel A, Carvalho JC. Ultrasound using the transverse approach to the lumbar spine provides reliable landmarks for labor epidurals. *Anesth Analg.* 2007;104:1188–1192.
- Balki M, Lee Y, Halpern S, Carvalho JC. Ultrasound imaging of the lumbar spine in the transverse plane: the correlation between estimated and actual depth to the epidural space in obese parturients. *Anesth Analg.* 2009; 108:1876–1881.
- Chin KJ, Perlas A, Singh M, et al. An ultrasound-assisted approach facilitates spinal anesthesia for total joint arthroplasty. *Can J Anesth.* 2009; 56:643–650.
- Cork RC, Kryc JJ, Vaughan RW. Ultrasonic localization of the lumbar epidural space. *Anesthesiology.* 1980;52:513–516.
- Currie JM. Measurement of the depth to the extradural space using ultrasound. *Br J Anaesth.* 1984;56:345–347.
- Ferre RM, Sweeney TW. Emergency physicians can easily obtain ultrasound images of anatomical landmarks relevant to lumbar puncture. *Am J Emerg Med.* 2007;25:291–296.
- Gnaho A, Nguyen V, Villevielle T, Frota M, Marret E, Gentili ME. Assessing the depth of the subarachnoid space by ultrasound. *Rev Bras Anesthesiol.* 2012;2:520–530.
- Grau T, Leipold RW, Conradi R, Martin E. Ultrasound control for presumed difficult epidural puncture. *Acta Anaesthesiol Scand.* 2001;45:766–771.
- Grau T, Leipold RW, Conradi R, Martin E, Motsch J. Ultrasound imaging facilitates localization of the epidural space during combined spinal and epidural anesthesia. *Reg Anesth Pain Med.* 2001;26:64–67.
- Grau T, Leipold RW, Conradi R, Martin E, Motsch J. Efficacy of ultrasound imaging in obstetric epidural anesthesia. *J Clin Anesth.* 2002; 14:169–175.
- Helayel PE, da Conceicao DB, Meurer G, Swarovsky C, de Oliveira Filho GR. Evaluating the depth of the epidural space with the use of ultrasound. *Rev Bras Anesthesiol.* 2010;60:376–382.
- Tran D, Kamani AA, Lessoway VA, Peterson C, Hor KW, Rohling RN. Preinsertion paramedian ultrasound guidance for epidural anesthesia. *Anesth Analg.* 2009;109:661–667.
- Vallejo MC, Phelps AL, Singh S, Orebaugh SL, Sah N. Ultrasound decreases the failed labor epidural rate in resident trainees. *Int J Obstet Anesth.* 2010;19:373–378.

33. Chin KJ, Perlas A, Chan V, Brown-Shreves D, Koshkin A, Vaishnav V. Ultrasound imaging facilitates spinal anesthesia in adults with difficult surface anatomic landmarks. *Anesthesiology*. 2011;115:94–101.
34. Grau T, Leipold RW, Fatehi S, Martin E, Motsch J. Real-time ultrasonic observation of combined spinal-epidural anaesthesia. *Eur J Anaesthesiol*. 2004;21:25–31.
35. Nomura JT, Leech SJ, Shenbagamurthi S, et al. A randomized controlled trial of ultrasound-assisted lumbar puncture. *J Ultrasound Med*. 2007;26:1341–1348.
36. Wang Q, Yin C, Wang TL. Ultrasound facilitates identification of combined spinal-epidural puncture in obese parturients. *Chin Med J (Engl)*. 2012;125:3840–3843.
37. Abdelhamid SA, Mansour AM. Ultrasound-guided intrathecal anesthesia: does scanning help? *Egypt J Anesth*. 2013;29:389–394.
38. Ansari T, Yousef A, El Gamassy A, Fayez M. Ultrasound-guided spinal anesthesia in obstetrics: is there an advantage over the landmark technique in patients with easily palpable spines? *Int J Obstet Anesth*. 2014;23:213–216.
39. Lim YC, Choo CY, Tan KT. A randomized controlled trial of ultrasound-assisted spinal anesthesia. *Anaesth Intensive Care*. 2014;42:191–198.
40. Mofidi M, Mohammadi M, Saidi H, et al. Ultrasound guided lumbar puncture in emergency department: time saving and less complications. *J Res Med Sci*. 2013;18:303–307.
41. Peterson MA, Pisupati D, Heyming TW, Abele JA, Lewis RJ. Ultrasound for routine lumbar puncture. *Acad Emerg Med*. 2014;21:130–136.
42. Sahin T, Balaban O, Sahin L, Solak M, Toker K. A randomized controlled trial of preinsertion ultrasound guidance for spinal anesthesia in pregnancy: outcomes among obese and lean parturients: ultrasound for spinal anesthesia in pregnancy. *J Anesth*. 2014;28:413–419.
43. Perlas A. Evidence for the use of ultrasound in neuraxial blocks. *Reg Anesth Pain Med*. 2010;35:S43–S46.
44. Moen V, Dahlgren N, Irestedt L. Severe neurological complications after central neuraxial blockades in Sweden 1990-1999. *Anesthesiology*. 2004;101:950–959.
45. Hamandi K, Mottershead J, Lewis T, Ormerod IC, Ferguson IT. Irreversible damage to the spinal cord following spinal anesthesia. *Neurology*. 2002;59:624–626.
46. Reynolds F. Damage to the conus medullaris following spinal anaesthesia. *Anaesthesia*. 2001;56:238–247.